



SPONTANEOUS RUPTURE OF EXTENSOR POLLICIS LONGUS TENDON: DEMONSTRATION OF EXTENSOR INDICIS PROPRIUS TRANSFER TECHNIQUE

Maharishi Markandeshwar Medical College and Hospital ¹, Solan,
All India Institute of Medical Sciences ², Bathinda,
India,

National Ilizarov Medical Research Center for Traumatology and Orthopedics
of Ministry of Healthcare ³, Kurgan,
The Russian Federation

В настоящее время при разрыве сухожилия длинного разгибателя большого пальца кисти нет единой схемы хирургического лечения. В статье представлен результат лечения пациента со спонтанным разрывом сухожилия длинного разгибателя большого пальца кисти в IV зоне по Б. Бойчеву, с подтверждением нарушения по данным ультразвукового исследования. В оперативном лечении нами был использован метод Pulvertaft (пересадка сухожилия собственного разгибателя указательного пальца на сухожилие длинного разгибателя большого пальца кисти). Через 3 месяца после операции пациент достиг полного объема движений большим пальцем и показал полное функциональное восстановление.

Ультразвуковое исследование может рассматриваться как достаточно точное и экономически выгодное диагностическое обследование при оценке случаев с подозрением на разрыв сухожилия длинного разгибателя большого пальца кисти и тендиозом. Этот случай показывает, что метод пересадки сухожилия собственного разгибателя указательного пальца на сухожилие длинного разгибателя большого пальца кисти является эффективным и надежным хирургическим пособием.

Ключевые слова: разгибатель большого пальца, повреждение сухожилия, спонтанное, Пулвертафт, хирургическая техника

Till now no single scheme of surgical treatment has gained wide acceptance in rupture of extensor pollicis longus tendon (EPL). The result of treatment of a patient with spontaneous rupture of EPL in IV zone by B. Boichev with ultrasonographic examination is presented in the paper. In surgical treatment we used Pulvertaft technique in transfer of tendon of m. extensor indicis proprius (EIP) to EPL. After 3 months of surgery the patient showed a full range of motions of the thumb joints and functional restoring. Ultrasonography can be considered as an accurate and cost effective diagnostic investigation in evaluation of cases with the suspected extensor pollicis longus tendon rupture and tendinosis. This case report shows that technique of EIP to EPL transfer is effective and reliable surgical option.

Keywords: extensor pollicis longus, tendon rupture, spontaneous, Pulvertaft, surgical technique

Novosti Khirurgii. 2020 Mar-Apr; Vol 28 (2): 233-239
Spontaneous Rupture of Extensor Pollicis Longus Tendon: Demonstration
of Extensor Indics Proprius Transfer Technique
T. Punit, H. Kaur, S.S. Leonchuk

The articles published under CC BY NC-ND license



Introduction

Commonly, the rupture of extensor pollicis longus tendon (EPL) results from a trauma, local injections of steroids prescribed for tenosynovitis, increased tendon friction at Lister's tubercle under certain occupational influences or the formation of degenerative osteophyte [1].

Of great importance in the pathogenesis of rupture of EPL tendon is given to the features of the canal and the course of the tendon (the tendon at the wrist passes in a separate tendon sheath (in carpal

ligament canal)) [2]. Particular attention is paid to the tendon vascularization, especially in adult patients. A decrease in vascularization leads to degeneration of the tendon and a slight permanent effect may subsequently cause a violation of its integrity [3].

However, a spontaneous rupture of EPL tendon in young housewives without any anatomical changes is very rare.

Objective. To demonstrate with a clinical example our approach to the diagnosis and treatment of spontaneous rupture to EPL tendon in a rare area.

Clinical case

A 40-year-old woman, a housewife, came to Maharishi Markandeshwar Medical College and Hospital with a sudden, painless loss of function of the thumb of her right hand over the past 6 weeks. She received conservative treatment, including physiotherapy, in the other clinic, but during this time she could not achieve recovery or even a slight improvement in function, and she was referred to our institution. There was no evidence of any injury, fracture, inflammatory arthritis, or corticosteroid injections. On examination, it turned out that she could not straighten her thumb at the interphalangeal joint, and EPL tendon was not palpable. Neurological examination revealed no changes. It was assumed that this was a case of rupture of the EPL tendon.

The ultrasound study showed an almost complete rupture of EPL tendon (Fig. 1) at the level of the Lister's tubercle (zone IV according

to B. Boychev [4]) with a hypoechoic region of a maximum thickness of 3 mm (Fig. 2), which suggested tendon hypertrophy. No evidence of any effusion was observed. This could be a thickening of the tendon sheath with tendon tendinosis. No inflammation or neovascularization of the tendon was noted. An X-ray examination of the patient's wrist and hand showed no signs of inflammatory arthritis, any tumors or osteophytes (Fig. 3).

We decided to proceed with the exploration of EPL tendon, which was identified through an incision in the metacarpophalangeal joint (MCP) (Fig. 4 A). At the same time, Lister's tubercle was visualized to search for any osteophyte or rough surface that could affect EPL tendon and cause it to rupture due to friction. However, we did not find any such structure. Despite the fact that EPL tendon was continuous, and this was confirmed by visualization through both accesses, when the tendon was easily mobilized with a vascular clamp without applying any force, it gave away with a

Fig. 1. Ultrasonographic longitudinal view image showing near complete disruption of EPL tendon.

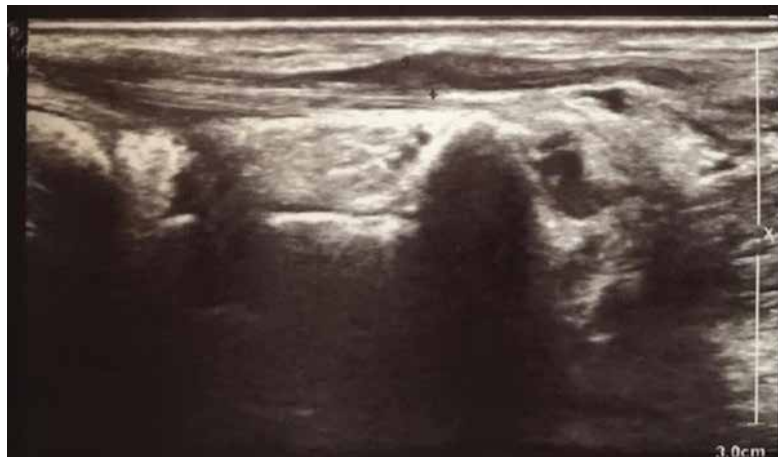
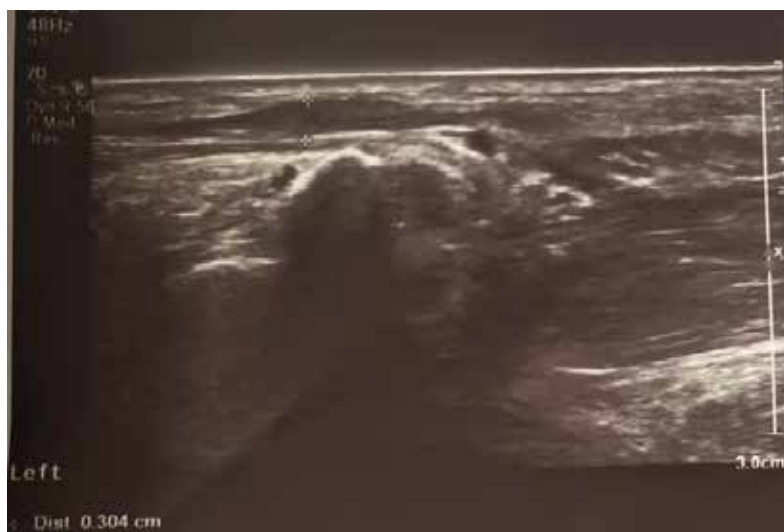
Fig. 2. Ultrasonographic view of EPL: hypoechoic area measuring about 3 mm at the site of tendon rupture.



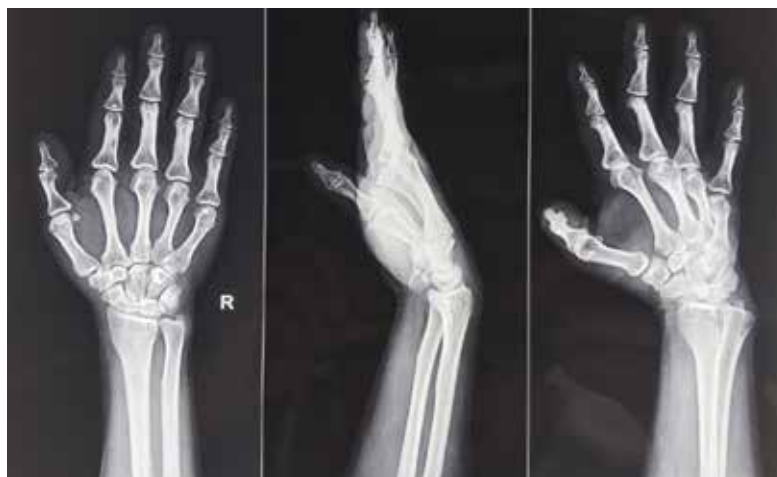

Fig. 3. Radiographs of the right upper limb without any pathology

“pop”. The distal stump of this tendon was retrieved through an incision above MCP. Its edge was uneven, shabby and degenerative (Fig. 4 A).

The tendon of its own extensor of the index finger (EIF) was visualized through access in the area of the second MCP joint (Fig. 4 B). The proximal end of the EIF tendon was sewed to the distal stump of the EPL tendon according to the method of Pulvertaft. (Fig. 4B).

The tension was adjusted so that when the wrist was extended, the thumb IP joint flexed and when the wrist flexed thumb IP joint extended. (Fig.5).

The patient’s thumb was immobilized with a brace within 2 weeks, after which the passive finger movements appeared; the patient began the exercise therapy. Thumb immobilization was completely withdrawn after 4 weeks.

3 months after the operation, the patient reached the full range of motion with her thumb and showed full functional recovery (Fig. 6).

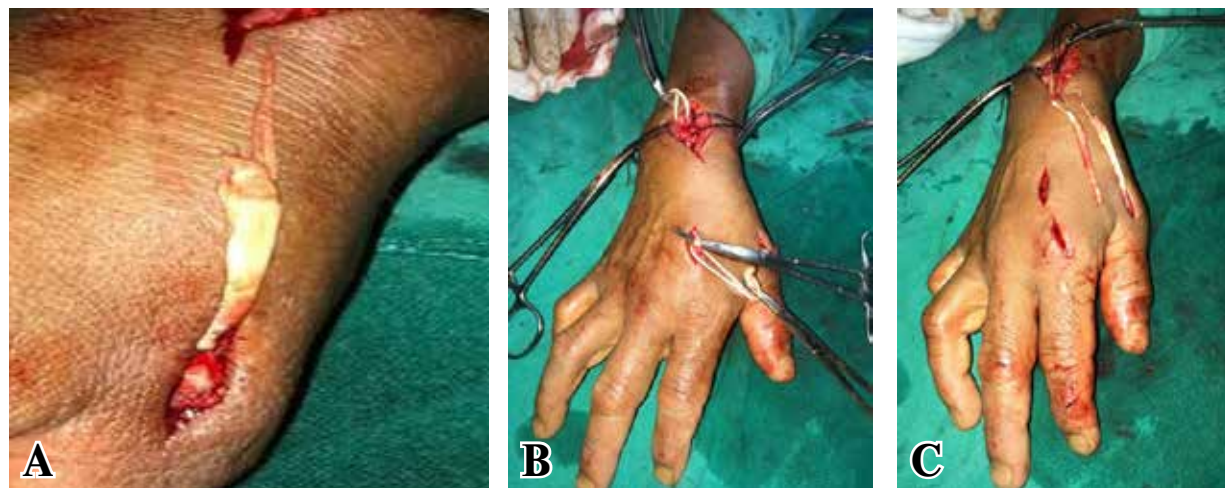
Discussion

Nowadays, in case of the rupture of EPL tendon, the transposition of various tendons of the extensor muscles is commonly used, however, there is no single treatment regimen. In our opinion, for this operation, the use of the tendon of its own extensor of the index finger (EIF) and the tendon of extensor carpi radialis longus (ECRL) are most beneficial for achieving an anatomical and functional result.

However, it is important to note that the disadvantage of using ECRL tendon is gap its significantly motion restriction than EPL tendon.

Tendinosis is a degeneration of tendon without clinical or histological signs of tendon inflammation and can even occur without any symptoms [5, 6, 7]. Many injuries commonly presumed to be tendinitis which is an acute pathology, are actually tendinosis hence underestimation of their chronic nature [5, 6, 7].

Fig. 4. Intraoperation view of the hand: A – zoomed view of EPL tendon showing degenerated, frayed margins; D – EIP tendon identified over haemostat in II MCP; C – EIP tendon allocated and its planned course before its attachment to distal EPL (Pulvertaft method).



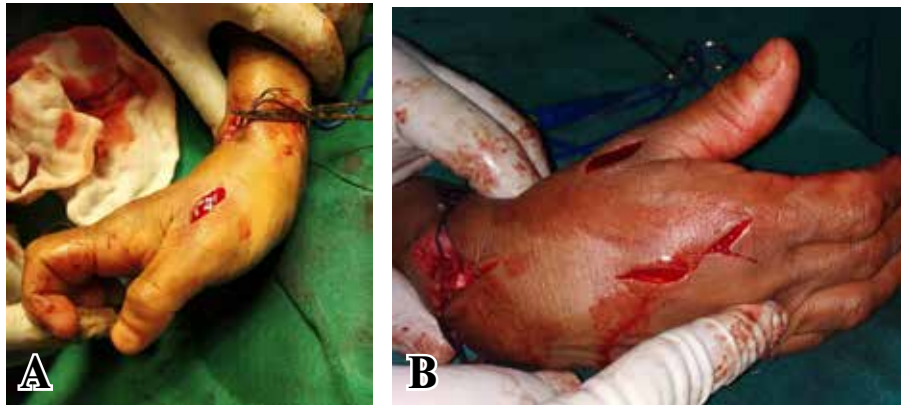


Fig. 5. Intraoperatively hand's view: A – thumb flexes passively with wrist extension; B – thumb extends passively with wrist in flexion.

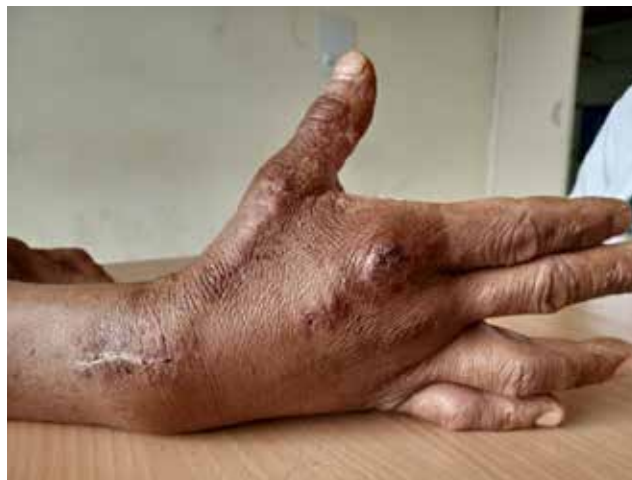

Fig. 6. Photo of patient's hand after 3 months of surgery.

Spontaneous rupture of EPL tendon should be considered in patients with a sudden loss of extensor movement in the interphalangeal joint of the thumb, even in the absence of any predisposing factor. The presence of a hypoechoic thickened zone in the area of disruption of collagen fibers indicates that the cause of the gap was not only a thinning, but also a degenerative process. In our opinion, ultrasound examination plays an important role in the process of confirmation of tendinitis and tendinosis.

According to M. De Maeseneer et al. [8], who used magnetic resonance imaging (MRI) to assess changes in the tendons of the wrist, MRI is not suitable for diagnosing changes in EPL tendon, since at the level of the wrist it has an inclined orientation of 50° relative to the usual plane of this study, which leads to a significant magic angle artefact. In addition, EPL tendon, unlike the adjacent passing tendons, is flat at the point of intersection of the extensor carpi radialis longus et brevis tendons and even under standard conditions, EPL tendon can be difficult to be visualized on MRI.

Ultrasound is a fairly accurate and cost-effective diagnostic study when evaluating cases with suspected rupture of EPL tendon.

Our ultrasound findings are consistent with those obtained by M. De Maeseneer et al. [8], since in our case there was also a tubular hypoechoic zone of about 3 mm in size in the area of violation of the continuity of collagen tendon fibers. However, we cannot comment on whether the synovial membrane was stretched at this point by fluid or hemorrhage, since the distal stump of the tendon was removed through a limited incision above the MPJ instead of a complete open visualization of the tendon along its entire length through a long skin incision.

Based upon a cadaveric study Low CK et al. [9] have recommended that keeping the wrist in neutral with the thumb in full extension with tension on the tendon allowed for a better range of thumb extension and flexion.

The more recent study by Jung SW et al. [10] compares the standard versus over-tensioning in the transfer of extensor indicis proprius tendon to extensor pollicis longus tendon for chronic rupture of the thumb extensor.

The authors concluded that, despite the acceptable functional results of the treatment of most patients in both groups, there were significant differences between the two groups in terms of range

of motion, lifting deficit and thumb strength.

Lee JH at al. [11] recommend that in EIP transfer, thumb in extension after transfer and EIP elongation for restoring thumb extension at the interphalangeal joint.

According to V.F. Baytinger, F.F. Kamolov [2] in case of damage to the EPL tendon, 1 finger of the hand should be fixed during flexion in MPJ 20°, flexion in the distal interphalangeal joint 10°.

The goal should be to avoid both the extensor lag as well as the limited thumb flexion so that an adequate grip can be achieved for both large as well as small objects, respectively.

We believe that, in addition, the magnitude of the tendon tension should be passively evaluated during the surgery, so that the thumb flexes in the interphalangeal joints when the wrist is extended and unbends when the wrist is flexed.

In most publications [3, 12, 13, 14, 15], it was described that the vast majority of patients with damage to EPL tendon were women over fifty years of age, and tendinosis in patients could be painless.

Eccentric exercises have the most convincing evidence of effectiveness among various conservative treatment options, including shock wave therapy, the use of corticosteroids and non-steroidal anti-inflammatory drugs, sclerosing injections, nitric oxide, injection of platelet-rich plasma and matrix metalloproteinase inhibitors [16].

Surprisingly, corticosteroid and non-steroidal anti-inflammatory drugs, according to the literature, have not proved their effectiveness in treating patients with tendinosis [16, 17].

Conclusion

So we conclude that it will not be an exaggeration to suggest that the orthopaedic surgeons should not hesitate to get ultrasonographic evaluation of EPL tendon done in all female patients in their forties and above who present to their clinics with wrist and thumb related complaints. Tendinosis in EPL tendon with thickened tendon sheath or a hypoechoic area should alert the orthopaedic surgeon about an impending rupture and loss of function even if the symptoms may be minimal. This case report shows that technique of EIP to EPL transfer is effective and reliable surgical option.

Funding

The research is carried out without sponsorship.

Conflict of interest

The authors declare that they have no conflict of interest.

The patient gave written informed consent to participate in the publication.

ЛИТЕРАТУРА

1. Björkman A, Jörgsholm P. Rupture of the extensor pollicis longus tendon: a study of aetiological factors. *Scand J Plast Reconstr Surg Hand Surg.* 2004;38(1):32-35. doi: 10.1080/02844310310013046
2. Байтингер ВФ, Камолов ФФ. Опыт хирургического лечения подкожного повреждения сухожилия длинного разгибателя I пальца кисти. *Вопр Реконструкт и Пласт Хирургии.* 2015;18(3):12-17. http://journals.tsu.ru/plastic_surgery/&journal_page=archive&id=1352&article_id=24683
3. Kim CH. Spontaneous rupture of the extensor pollicis longus tendon. *Arch Plast Surg.* 2012 Nov;39(6):680-82. Published online 2012 Nov 14. doi: 10.5999/aps.2012.39.6.680
4. Бойчев Б, Холевич Я, ред. Хирургия кисти и пальцев [Электронный ресурс]. София: Медицина и физкультура; 1971. 316 с. <https://studfiles.net/preview/1213673/>
5. Maffulli N, Wong J, Almekinders LC. Types and epidemiology of tendinopathy. *Clin Sports Med.* 2003 Oct;22(4):675-92. doi: 10.1016/S0278-5919(03)00004-8
6. Maffulli N, Khan KM, Puddu G. Overuse tendon conditions: time to change a confusing terminology. *Arthroscopy.* 1998 Nov-Dec;14(8):840-43. doi: 10.1016/S0749-8063(98)70021-0
7. Bass E. Tendinopathy: why the difference between tendinitis and tendinosis matters. *Int J Ther Massage Bodywork.* 2012;5(1):14-17. doi: 10.3822/ijtmb.v5i1.153
8. De Maeseneer M, Marcelis S, Osteaux M, Jager T, Machiels F, Van Roy P. Sonography of a rupture of the tendon of the extensor pollicis longus muscle: initial clinical experience and correlation with findings at cadaveric dissection. *AJR Am J Roentgenol.* 2005 Jan;184(1):175-79. doi: 10.2214/ajr.184.1.01840175
9. Low CK, Pereira BP, Chao VT. Optimum tensioning position for extensor indicis to extensor pollicis longus transfer. *Clin Orthop Relat Res.* 2001 Jul;(388):225-32. doi: 10.1097/00003086-200107000-00031
10. Jung SW, Kim CK, Ahn BW, Kim DH, Kang SH, Kang SS. Standard versus over-tensioning in the transfer of extensor indicis proprius to extensor pollicis longus for chronic rupture of the thumb extensor. *J Plast Reconstr Aesthet Surg.* 2014 Jul;67(7):979-85. doi: 10.1016/j.bjps.2014.03.006
11. Lee JH, Cho YJ, Chung DW. A New Method to Control Tendon Tension in the Transfer of Extensor Indicis Proprius to Extensor Pollicis Longus Rupture. *Ann Plast Surg.* 2015 Dec;75(6):607-9. doi: 10.1097/SAP.0000000000000593
12. Jain A, Goyal N, Mishra P. Spontaneous rupture of EPL and ECRB tendons in a washerwoman: an unusual phenomenon. *Hand Surg.* 2014;19(2):241-44. doi: 10.1142/S0218810414720186
13. Zinger G, Dalu KA, Bregman A, Yudkevich G. Spontaneous Rupture of the Extensor Pollicis Longus Tendon With Repair and Contralateral Prophylactic Decompression: A Case Report and Review of the Literature. *J Hand Surg Am.* 2019 Aug;44(8):702.e1-702.e5. doi: 10.1016/j.jhsa.2018.09.011
14. Hu CH, Fufa D, Hsu CC, Lin YT, Lin CH. Revisiting spontaneous rupture of the extensor pollicis longus tendon: eight cases without identifiable predisposing factor. *Hand (NY).* 2015 Dec;10(4):726-

31. doi: 10.1007/s11552-015-9746-y

15. Ta S, Balta S, Benlier E. Spontaneous rupture of the extensor pollicis longus tendon due to unusual etiology. *Balkan Med J.* 2014 Mar;31(1):105-106. doi: 10.5152/balkanmedj.2013.9027

16. Magnussen RA, Dunn WR, Thomson AB. Nonoperative treatment of midportion Achilles tendinopathy: a systematic review. *Clin J Sport Med.* 2009 Jan;19(1):54-64. doi: 10.1097/JSM.0b013e31818ef090

17. Andres BM, Murrell GA. Treatment of tendinopathy: what works, what does not, and what is on the horizon. *Clin Orthop Relat Res.* 2008 Jul;466(7):1539-54. doi: 10.1007/s11999-008-0260-1

REFERENCES

1. Björkman A, Jörgsholm P. Rupture of the extensor pollicis longus tendon: a study of aetiological factors. *Scand J Plast Reconstr Surg Hand Surg.* 2004;38(1):32-35. doi: 10.1080/02844310310013046

2. Baitinger VF, Kamolov FF. Experience of surgical treatment of subcutaneous tendon damage long extensor of the thumb. *Vopr Rekonstrukt i Plast Khirurgii.* 2015;18(3):12-17 http://journals.tsu.ru/plastic_surgery/&journal_age=arc_hive&id=1352&article_id=24683 (In Russ.)

3. Kim CH. Spontaneous rupture of the extensor pollicis longus tendon. *Arch Plast Surg.* 2012 Nov;39(6):680-82. Published online 2012 Nov 14. doi: 10.5999/aps.2012.39.6.680

4. Boichev B, Kholevich Ia, red. *Khirurgiia kisti i pal'tsev [Elektronnyi resurs].* Sofiia: Meditsina i fizkul'tura; 1971. 316 p. <https://studfiles.net/preview/1213673/> (In Russ.)

5. Maffulli N, Wong J, Almekinders LC. Types and epidemiology of tendinopathy. *Clin Sports Med.* 2003 Oct;22(4):675-92. doi: 10.1016/S0278-5919(03)00004-8

6. Maffulli N, Khan KM, Puudu G. Overuse tendon conditions: time to change a confusing terminology. *Arthroscopy.* 1998 Nov-Dec;14(8):840-43. doi: 10.1016/S0749-8063(98)70021-0

7. Bass E. Tendinopathy: why the difference between tendinitis and tendinosis matters. *Int J Ther Massage Bodywork.* 2012;5(1):14-17. doi: 10.3822/ijtmb.v5i1.153

8. De Maeseneer M, Marcelis S, Osteaux M, Jager T, Machiels F, Van Roy P. Sonography of a rupture

of the tendon of the extensor pollicis longus muscle: initial clinical experience and correlation with findings at cadaveric dissection. *AJR Am J Roentgenol.* 2005 Jan;184(1):175-79. doi: 10.2214/ajr.184.1.01840175

9. Low CK, Pereira BP, Chao VT. Optimum tensioning position for extensor indicis to extensor pollicis longus transfer. *Clin Orthop Relat Res.* 2001 Jul;(388):225-32. doi: 10.1097/00003086-200107000-00031

10. Jung SW, Kim CK, Ahn BW, Kim DH, Kang SH, Kang SS. Standard versus over-tensioning in the transfer of extensor indicis proprius to extensor pollicis longus for chronic rupture of the thumb extensor. *J Plast Reconstr Aesthet Surg.* 2014 Jul;67(7):979-85. doi: 10.1016/j.bjps.2014.03.006

11. Lee JH, Cho YJ, Chung DW. A New Method to Control Tendon Tension in the Transfer of Extensor Indicis Proprius to Extensor Pollicis Longus Rupture. *Ann Plast Surg.* 2015 Dec;75(6):607-9. doi: 10.1097/SAP.0000000000000593

12. Jain A, Goyal N, Mishra P. Spontaneous rupture of EPL and ECRB tendons in a washerwoman: an unusual phenomenon. *Hand Surg.* 2014;19(2):241-44. doi: 10.1142/S0218810414720186

13. Zinger G, Dalu KA, Bregman A, Yudkevich G. Spontaneous Rupture of the Extensor Pollicis Longus Tendon With Repair and Contralateral Prophylactic Decompression: A Case Report and Review of the Literature. *J Hand Surg Am.* 2019 Aug;44(8):702.e1-702.e5. doi: 10.1016/j.jhsa.2018.09.011

14. Hu CH, Fufa D, Hsu CC, Lin YT, Lin CH. Revisiting spontaneous rupture of the extensor pollicis longus tendon: eight cases without identifiable predisposing factor. *Hand (NY).* 2015 Dec;10(4):726-31. doi: 10.1007/s11552-015-9746-y

15. Ta S, Balta S, Benlier E. Spontaneous rupture of the extensor pollicis longus tendon due to unusual etiology. *Balkan Med J.* 2014 Mar;31(1):105-106. doi: 10.5152/balkanmedj.2013.9027

16. Magnussen RA, Dunn WR, Thomson AB. Nonoperative treatment of midportion Achilles tendinopathy: a systematic review. *Clin J Sport Med.* 2009 Jan;19(1):54-64. doi: 10.1097/JSM.0b013e31818ef090

17. Andres BM, Murrell GA. Treatment of tendinopathy: what works, what does not, and what is on the horizon. *Clin Orthop Relat Res.* 2008 Jul;466(7):1539-54. doi: 10.1007/s11999-008-0260-1

Адрес для корреспонденции

640014, Российская Федерация,
г. Курган, ул. Марии Ульяновой, 6,
Национальный медицинский
исследовательский центр травматологии
и ортопедии имени академика Г.А. Илизарова,
6-ое травматолого-ортопедическое отделение,
тел.: +7 905 8516338,
e-mail: leon4yk@mail.ru,
Леончук Сергей Сергеевич

Сведения об авторах

Tiwari Punit, травматолог-ортопед, ассистент профессора, отделение ортопедии, Maharishi Markandeshwar Medical College and Hospital, г. Солан, Индия.

<https://orcid.org/0000-0002-4174-8344>

Harmeet Kaur, врач лучевой диагностики, ассистент профессора, отделение лучевой диагностики, All

Address for correspondence

640014, Russian Federation,
Kurgan, ul. M. Ulyanova, 6,
National Ilizarov Medical Research
Center for Traumatology and Orthopedics
of Ministry of Healthcare,
6th traumatologic-orthopaedic department,
mob. +7 905 8516338,
e-mail: leon4yk@mail.ru
Sergey S. Leonchuk

Information about the authors

Tiwari Punit, Orthopedic Traumatologist, Assistant Professor, Orthopedics Department, Solan city, Himachal Pradesh state, India.

<https://orcid.org/0000-0002-4174-8344>

Harmeet Kaur, Radiologist, Assistant Professor, Department of Radial Diagnosis, All India Institute of Medical Sciences, Bathinda city, Punjab state, India

India Institute of Medical Sciences, г. Батинда, Индия.
<https://orcid.org/0000-0001-7962-8463>
Леончук Сергей Сергеевич, к.м.н., заведующий 6-м
травматолого-ортопедическим отделением, Наци-
ональный медицинский исследовательский центр
травматологии и ортопедии имени академика Г.А.
Илизарова, г. Курган, Российская Федерация.
<https://orcid.org/0000-0003-0883-9663>

Информация о статье

*Поступила 3 августа 2019 г.
Принята в печать 13 апреля 2020 г.
Доступна на сайте 15 мая 2020 г.*

<https://orcid.org/0000-0001-7962-8463>
Leonchuk Sergey S., Candidate of Medical Sciences
(PhD), Head of the 6th Orthopedic department, National
Iizarov Medical Research Center for Traumatology
and Orthopedics of Ministry of Healthcare, Kurgan,
Russian Federation.
<https://orcid.org/0000-0003-0883-9663>

Article history

*Arrived: 03 August 2019
Accepted for publication: 13 April 2020
Available online: 15 May 2020*
