

V. SIHOTSKY <sup>1,2</sup>, I. KOPOLOVETS <sup>1,3</sup>, M. KUBIKOVA <sup>1,2</sup>,  
P. STEFANIC <sup>1,2</sup>, V. KATUCH <sup>2</sup>



## RESULTS OF SURGICAL TREATMENT OF PATIENTS WITH AORTOILIAC ATHEROSCLEROSIS

Eastern Slovak Institute of Cardiovascular Diseases <sup>1</sup>,  
Pavol Jozef Safarik University <sup>2</sup>, Kosice,  
the Slovak Republic  
Uzhhorod National University <sup>3</sup>, Uzhhorod,  
Ukraine

**Цель.** Изучить результаты хирургического лечения пациентов с аорто-подвздошной патологией в раннем послеоперационном периоде.

**Материал и методы.** В исследование включено 103 пациента с аортальной патологией, которые были направлены в клинику сосудистой хирургии с 2015 по 2017 год. Прооперировано 53 пациента с аорто-подвздошным атеросклерозом и 50 пациентов с аневризмой абдоминальной аорты. Показанием к операции были перемежающаяся хромота, критическая ишемия конечности или острый тромбоз аорты у пациентов с аорто-подвздошным атеросклерозом. Показанием к операции у пациентов с аневризмой абдоминальной аорты была аневризма более 5,5 см в поперечном диаметре или разрыв аневризмы. Ранние результаты хирургического лечения пациентов оценивали по частоте послеоперационных осложнений и летальных исходов.

**Результаты.** Из 53 пациентов с аорто-подвздошным атеросклерозом 49 (92,5%) пациентов были прооперированы в плановом порядке и 4 (7,5%) пациента были прооперированы urgently. Выполнено 52 (98,2%) аорто-бифemorальных шунтирования и один (1,8%) аорто-фemorальный (односторонний) шунт. Три осложнения (6,1%) наблюдались у пациентов, которые были прооперированы в плановом порядке, и одно осложнение (25%) у пациента, которого оперировали в urgentном порядке. Среди urgentных пациентов смертность составила 25%, среди плановых – 2,0%. Прооперированы 28 пациентов с бессимптомной аневризмой абдоминальной аорты и 22 пациента с разрывом аневризмы абдоминальной аорты. Смертность после плановой операции составила 3,6%. У пациентов с разрывом аневризмы абдоминальной аорты смертность составила 40,9%.

**Заключение.** Хорошие и удовлетворительные результаты планового хирургического лечения симптоматического аорто-подвздошного атеросклероза в раннем послеоперационном периоде составили 98%, асимптоматической аневризмы аорты – 96,4%. Смертность после urgentной операции при разрыве аневризмы составила 40,9%. Хирургическое лечение аневризмы аорты показано у пациентов с низким и средним хирургическим риском.

*Ключевые слова:* атеросклероз, аневризма аорты, критическая ишемия конечности, аорто-подвздошная реконструкция

**Objective.** To investigate the results of surgical treatment of patients with aortoiliac pathology in the early postoperative period.

**Methods.** In the study 103 patients with aortoiliac pathology were included, who were referred to the Clinic of Vascular Surgery from 2015 to 2017 years. 53 patients were operated on because of aortoiliac atherosclerosis and 50 patients – because of abdominal aortic aneurysm. The indications for surgery were limiting claudication, critical limb ischemia or acute thrombosis of the aorta in patients with aortoiliac atherosclerosis. The indication for surgery in patients with abdominal aortic aneurysm was the aneurysm over 5.5 cm in the transverse diameter or the ruptured aneurysm. Early results of patients' surgical treatment were assessed by the frequency of postoperative complications and deaths.

**Results.** 49 (92.5%) out of 53 patients with aortoiliac atherosclerosis were operated on as planned and 4 (7.5%) patients were operated on urgently. 52 (98.2%) aortobifemoral bypasses and one (1.8%) aortofemoral (unilateral) bypass were performed. Three complications (6.1%) occurred postoperatively in patients operated on according to plan and one complication (25%) – in patients operated urgently. The mortality rate was 25% in urgent patients and 2.0% in planned patients. 28 patients with asymptomatic abdominal aortic aneurysm and 22 with the ruptured abdominal aortic aneurysm were operated on. The mortality in the planned patients was 3.6%. 40.9% mortality rate was registered in the ruptured abdominal aortic aneurysm patients.

**Conclusions.** Early good and satisfactory results of the routine surgical treatment of symptomatic aortoiliac atherosclerosis in the early postoperative period accounted 98%, asymptomatic aortic aneurysm – 96.4%. Mortality after urgent surgery with aneurysm rupture made up 40.9%. Surgical treatment of aortic aneurysm is indicated in patients with low and moderate surgical risk.

*Keywords: atherosclerosis, aortic aneurysms, critical limb ischemia, aortoiliac reconstructions*

**Novosti Khirurgii. 2019 May-Jun; Vol 27 (3): 276-283**  
**Results of Surgical Treatment of Patients with Aortoiliac Atherosclerosis**  
**V. Sihotsky, I. Kopolovets, M. Kubikova, P. Stefanic, V. Katuch**

The articles published under CC BY NC-ND license



### Научная новизна статьи

Установлено, что смертность плановой открытой аортальной операции при абдоминальных аневризмах составляет около 3,6%, смертность при разрыве аневризмы достигает 40,9%.

### What this paper adds

It has been established that the mortality rate of the planned open aortic surgery for abdominal aneurysms is about 3.6%, the mortality rate after the rupture of the aneurysm reaches 40.9%.

## Introduction

Aortoiliac reconstruction represents the possibilities of surgical treatment of atherosclerosis, both obliterating disease and aortoiliac aneurysm. The first aortoiliac reconstruction was performed by Wylie in the USA, who in 1951 did aortic bifurcation thrombendarterectomy in atherosclerotic obliteration [1]. The first reconstruction of an aortic aneurysm was carried out by Dubost in Paris in 1951. He restored continuity after resection of the aortic aneurysm rupture using a preserved human aortic graft [1]. But the further development of the aortoiliac reconstruction was impossible due to the lack of aortic allografts, which represented the only possibility of restoring aortic continuity. The golden era of aortoiliac reconstructions began with the invention of aortic-bifemoral shunts [2]. The introduction of endovascular treatment of aortic pathologies was the second important factor that changed the possibilities of treatment. At the beginning of our millennium, the widespread development of interventional procedures changed the approach to the treatment of aortoiliac pathology. Aortoiliac reconstruction is performed as a surgical treatment of aortoiliac atherosclerosis, which cannot be treated endovascularly, mainly to TASC D patients, according to the TASC (Trans-Atlantic Inter-Society Consensus) classification [3]. Surgical treatment of abdominal aortic aneurysm (AAA) is indicated for asymptomatic treatment in patients with aneurysms with the diameter of more than 5.5 cm in cross section or in the rupture of AAA [4].

According to the updated AAA treatment guidelines, according to the European Society of Vascular Surgery (ESVS) from 2019, surgical treatment is an option for patients with a life expectancy of more than 10-15 years. Routine AAA surgery is not recommended for patients with terminal cancer, patients with severe heart failure and a life expectancy of less than 2-3 years. [5, 6].

**Objective.** To investigate the results of surgical treatment of patients with aortoiliac pathology in the early postoperative period.

## Methods

The study was conducted in the Clinic of Vascular Surgery of Eastern Slovak Institute of Cardiovascular Diseases, Kosice, Slovakia. A retrospective study included 103 patients with aortoiliac pathology who were referred to the department from January 2015 to December 2017. 53 patients with aortoiliac atherosclerosis and 50 patients with AAA were operated on. Indications for surgery were intermittent claudication, critical limb ischemia or acute aortic thrombosis in patients with aortoiliac atherosclerosis. The diagnosis of aortoiliac atherosclerosis was based on CT angiography or angiography. Indications for surgery were exposed to patients with AAA more than 5.5 cm in transverse diameter and all patients with the aneurysm rupture. The diagnosis of AAA was established using ultrasound and CT angiography.

## Results

Aortoiliac atherosclerosis. 49 (92.5%) out of 53 patients with aortoiliac atherosclerosis were operated on in the planned manner and 4 (7.5%) patients were operated urgently (Table 1).

52 (98.2%) aortic-bifemoral bypass operations and one (1.8%) aortic-femoral (one-sided) shunting to the right due to the superimposed sigmoidostomy were performed. Aortic-bifemoral bypass was performed using a Dacron prosthesis, the proximal anastomosis was standardized by the side-to-end principle. Distal anastomoses were placed in the common femoral artery with the continuation of the anastomosis to the end-to-side deep femoral artery.

Additional interventions of aortic-bifemoral bypass were: AAA resection with the end-to-end anastomosis in 2 patients, aortic thrombectomy in 8 patients due to subrenal aortic thrombosis, and in one patient the lower mesenteric artery was re-implanted to prevent left ischemic ischemia (Table 2).

There were four complications requiring reoperation after aortic reconstruction: three complications (6.1%) occurred in patients who were operated on in a planned manner (bleeding in one patient and prosthetic thrombosis in two

Table 1

Aortoiliac reconstructions carried out in the department for 2015-2017		
Diagnosis	Number	%
Aortoiliac atherosclerosis – planned	49	47.6%
Aortoiliac atherosclerosis – urgent	4	3.9%
Abdominal aortic aneurysm (planned)	28	27.2%
Abdominal aortic aneurysm rupture	22	21.4%
All patients	103	100%

Table 2

Additional interventions for aortobifemoral bypass. Aneurysm of the abdominal aorta		
Additional interventions	Number	%
Additional interventions in aortic-bifemoral bypass	53	100%
Abdominal aortic aneurysm resection and end-to-end anastomosis	2	3.8%
Subrenal aortic thrombectomy	8	15.1%
Reimplantation of the inferior mesenteric artery	1	1.8%
Planned operations	49	92.5%
Urgent operations	4	7.5%

Table 3

Complications requiring surgery			
Complications		Number	%
Planned surgeries	Bleeding	1	2%
	Thrombosis of limb arteries	2	4.1%
		3	6.1%
	Shunt thrombosis – acute	1	25%
Urgent surgeries		1	25%
Total		4	8.1%

patients); one complication (25%) requiring surgical intervention in a patient (prosthetic thrombosis), which was operated on urgently (Table 3)

One patient died (25%) of all urgent patients in the postoperative period; and one patient died operated on in a planned manner (2.0%).

**Aneurysm of the abdominal aorta.** 28 surgical interventions for asymptomatic AAA were performed. Aortic shunting was performed in 15 patients using the dacron prosthesis when the iliac arteries were not involved in the aneurysm process. In 13 cases, aortic-bifemoral bypass was performed, when the common iliac arteries were expanded by more than 2.5 cm. In cases of aortic-bifemoral bypass, the proximal anastomosis was done end-to-end, and the distal – end-to-side. In the case of aorto-aortic prosthesis, the proximal and distal anastomoses were performed end-to-end. Aortic-bifemoral bypass was performed using the dacron prosthesis, the distal anastomoses were sutured into the common femoral artery with the continuation of the anastomosis to the deep femoral artery. The lower mesenteric artery was reimplanted into the prosthesis in four patients (Fig. 1).

Reimplantation was performed to prevent ischemia of the left colon, when both internal iliac arteries were transected and ligated during the surgery. One patient died after the planned surgery; the mortality rate was 3.6%. (Table 4).

22 patients were operated on due to rupture of AAA. Eleven aorto-aortic reconstructions, 9 aortic-bifemoral reconstructions, and 2 explorative laparotomies were performed when patients died during the surgical resuscitation. In one patient with suprarenal AAA, it became necessary to reimplant both renal arteries. Eight patients (36%) needed reoperations: three due to acute limb ischemia, two due to postoperative bleeding, one due to perforation of peptic ulcer, one due to acute coronary syndrome and one due to infection after laparotomy (Table 5). Nine patients (40.9%) died in the postoperative period after urgent surgery.

**Fig. Reimplantation of the inferior mesenteric artery.**

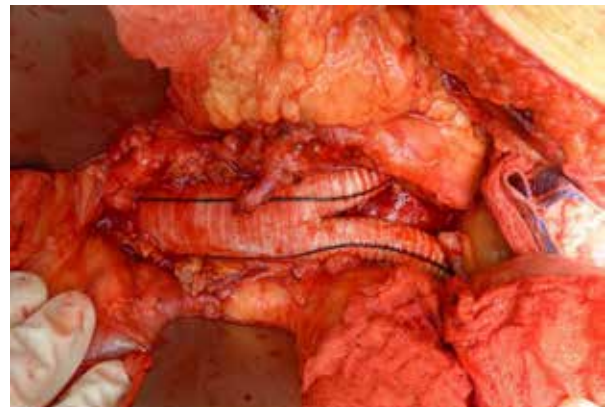


Table 4

<b>Surgical interventions and complications of asymptomatic abdominal aortic aneurysm</b>			
	Aortic reconstruction	Number	%
Total	Aorto-aortic prosthesis	15	54%
	Aortic-bifemoral bypass	13	46%
	Repeated implantation of the inferior mesenteric artery	4	14.2%
		28	100%
Total complications	Complications requiring reoperation		
	Bleeding	2	7.1%
	Complications in the groin area	1	3.6%
	Infection	1	3.6%
Mortality		4	14.2%
		1	3.6%

Table 5

<b>Surgical interventions and complications in rupture of the abdominal aortic aneurysm</b>			
	Aortic reconstructions	22	100%
Mortality	Aorto-aortic prosthesis	11	50%
	Aortic-bifemoral bypass	9	41%
	Expiratory laparotomy	2	9%
	Repeated implantation of the renal arteries	1	4.5%
		9	40.9%

### Discussions

Aortoiliac reconstructions are performed mainly in atherosclerosis or aneurysm of the aorta and aortoiliac segment. Surgeries are indicated for patients with TASC C or TASC D lesions according to the TASC classification [3]. Aortic-bifemoral bypass is the “gold standard” for the treatment of symptomatic aortoiliac atherosclerosis. There are two possible access to the abdominal aorta: transperitoneal and retroperitoneal, both acceptable and have similar results [1]. Aortic reconstructions are performed mainly with the prosthesis “Dacron”. It is preferable that the proximal aorta anastomosis is designed side-to-end, which is technically not so difficult, and also allows for blood flow to the lumbar and pelvic arteries and, therefore, prevents pelvic ischemia [2]. The end-to-end anastomosis is appropriate in cases of AAA or in the case of very common aortic atherosclerosis, when only a small portion of the subrenal aorta is soft [7]. In such situations, the proximal anastomosis is performed on the cross-clamping aorta. In our group of patients, we performed the end-to-end anastomosis in only two (3.8%) patients who had AAA. In one patient, we reimplemented the inferior mesenteric artery to prevent ischemia of the left colon. The distal anastomosis should be placed on the common femoral artery with the continuation of the anastomosis on the deep femoral artery to prevent the stenosis of the latter in future. Stenosis of the deep femoral artery can lead to limb thrombosis. Profundoplasty plays an important role in maintaining the long-term patency of aortic-bifemoral bypass operations [8].

Aortic-bifemoral bypass is a safe procedure with a very low mortality rate, up to 2% and a 10-year patency of 75-85% [7]. In the presented patients, the complication rate in planned cases was 6.1%, mortality - 2.0%. The level of complications and mortality in urgent patients were higher: the complication rate was 25% and the mortality rate was 25% among urgent patients. One patient had the prosthesis thrombosis and one patient died in the postoperative period. Thus, it is important to carry out surgical interventions in patients at the stage of a stable course of the disease and to prevent acute occlusion in which there is a high mortality rate of up to 22% [8]. About 60% of patients with aortoiliac atherosclerosis also have peripheral artery disease [9]. In 80% of patients with aortoiliac and femoral atherosclerosis, the symptoms of ischemia are reduced after aortic-bifemoral bypass surgery, and only 20% of them require reconstruction of the femoral-popliteal arterial segment after aortic-bifemoral bypass [5]. Taking into consideration these excellent long-term indices of patency, aortic-bifemoral bypass is currently considered the method of choice for revascularization [2].

Another possibility of aortoiliac reconstructions is aortic endarterectomy. Despite this procedure was the first aortoiliac reconstruction, it is not commonly used today. The only advantage of endarterectomy compared with aorto-bifemoral bypass is the absence of prosthetic material, but the endarterectomy has been replaced by bypass operations [6].

Another possibility to manage aortoiliac atherosclerosis is to perform revascularization of

one iliac artery, either endovascularly or surgically, and then apply an extraanatomical femoro-femoral bypass. Cross-shunting has a lower long-term patency compared with aortic-bifemoral bypass, but does not require laparotomy, so it is intended for polymorbid patients who are not suitable for aortic surgery. The five-year patency of femoro-femoral bypass is about 70% [9]. But in patients with low and moderate surgical risk, we prefer aortic-bifemoral bypass.

Aneurysms of the abdominal aorta are indications for surgeries in cases where the transverse diameter exceeds 55 mm, when aneurysmal expansion of more than 10 mm occurs in one year or in case of a rupture [10]. The diagnosis of AAA is based on CT angiography. CT angiography accurately determines the proximal and distal part of AAA, more accurately depicts the iliac arteries and provides important information for the operation planning. This is especially true for modern multi-detector spiral CT with thin sections in the place of interest [6]. Ultrasound is suitable as a screening method, but not as a final diagnostic method in patients with AAA for the planned surgery. However, ultrasound is the key method in unstable AAA rupture patients, which should be used immediately, since CT angiography can lead to delay, intra-abdominal rupture and patient's death [4].

Both approaches of surgical access (transperitoneal and retroperitoneal) can be used during aortic surgery. The choice of surgical access should be determined by the preference of the surgeon and his qualifications [11]. If the aortic aneurysm does not extend to the iliac arteries, end-to-end aorto-aortic prosthesis is performed. In cases of aneurysm of the iliac arteries, aortoiliac or aorto-bifemoral bypass surgery should be performed. The indication for the reconstruction of iliac aneurysm is its diameter of more than 2.5 cm with concomitant aortic surgery or 3.5 cm with an isolated reconstruction of the iliac aneurysm. [1, 12]. Aortoiliac reconstruction is preferred for comorbidities, due to the absence of inguinal incisions. We have good experience of aortic-bifemoral bypass in cases of concomitant aortic and iliac aneurysms. Anastomosis in the common femoral artery is not as technically complex as the end-to-end anastomosis in the iliac arteries in the pelvic region, especially in obese men or when aneurysm ruptures. Early mortality after open surgery on aneurysms ranges from 5% to 8% [6]. In the presented material, the mortality after planned surgery of aortic aneurysm was 3.6%. Perioperative complications were observed in 14.6% of patients who were operated on as planned patients.

Recently, a higher increase in endovascular

interventions has been registered, resulting in the fact that up to 60% of planned AAA cases in the USA are being treated with endovascular methods and the open surgical method is reserved for patients with anatomy that is not suitable for EVAR (EndoVascular Aneurysm Repair) [13]. But recent results from randomized controlled studies of EVAR-1 and EVAR-2, after 15 years, have shown that EVAR does not exceed open reconstruction. EVAR has a better early survival rate, but inferior in late survival compared with open operations [5]. EVAR also has a higher rate of reintervention than open surgery. In general, the frequency of repeated interventions with aneurysm was higher in the EVAR group than in the group of open operations: 4.1 and 1.7 per 100 person-years, respectively ( $p < 0.001$ ), with repeated interventions occurring during the observation [14].

Open AAA operations are indicated for patients with low and moderate surgical risk, and EVAR should be considered in patients with high surgical risk or in patients after multiple abdominal surgeries [6]. Results obtained for over 15 years of observation suggest that EVAR does not prolong life in patients unsuitable for open surgery [14].

Mortality in the reconstruction of AAA rupture is up to 50.8%. Aortic rupture leads to a combination of reperfusion injuries, hemorrhagic shock, lower trunk ischemia and multiorgan failure [11]. In the examined group of patients, the mortality after urgent surgery for the aneurysm rupture was 40.9%.

The only randomized study that assessed death and severe complications of AAA rupture was the Dutch multicenter randomized study (AJAX). AJAX results show that death and severe complications occur in 21% of patients after EVAR and in 25% after open repair of the AAA rupture, as is evident, there is no significant difference [15]. In patients with rupture of the abdominal aortic aneurysm, EVAR may be useful in case of appropriate anatomy for endovascular treatment.

## Conclusions

Good and satisfactory results of planned surgical treatment of symptomatic aortoiliac atherosclerosis in the early postoperative period amounted up to 98%, asymptomatic aortic aneurysm - 96.4%. Mortality after urgent surgery with the aneurysm rupture was 40.9%. Surgical treatment of aortic aneurysm is indicated in patients with low and moderate surgical risk.

## Funding

The work was carried out in accordance with the scientific plans of the Clinic of Vascular Surgery

of Eastern Slovak Institute of Cardiovascular Diseases, Kosice, the Slovak Republic.

The authors did not receive any financial support from manufacturers of medical products.

### Conflict of interest

The authors declare that they have no conflict of interest.

### Ethical aspects Ethics Committee approval

The research is approved by the Ethics Committee of Eastern Slovak Institute of Cardiovascular Diseases, Kosice, the Slovak Republic.

### ЛИТЕРАТУРА

1. Menard MT. Aortoiliac Disease: Direct Aortoiliac Reconstruction. In: Cronenwett JL, Johnston KW. Rutherford's Vascular Surgery. 8<sup>th</sup> ed. Philadelphia: Elsevier Saunders; 2014. p. 1701-21. <https://www.uk.elsevierhealth.com/rutherford-s-vascular-surgery-2-volume-set-9781455753048.html>
2. Jaquinandi V, Picquet J, Saumet JL, Benharash P, Leftheriotis G, Abraham P. Functional assessment at the buttock level of the effect of aortobifemoral bypass surgery. *Ann Surg.* 2008 May;247(5):869-76. doi: 10.1097/SLA.0b013e31816bcd75
3. Norgren L, Hiatt WR, Dormandy JA, Nehler MR, Harris KA, Fowkes FG, Rutherford RB. Inter-society consensus for the management of peripheral arterial disease (TASC II). *J Vasc Surg.* 2007 Jan;45(1s 1 Suppl):S5-S67. doi: <https://doi.org/10.1016/j.jvs.2006.12.037>
4. Moll FL, Powell JT, Fraedrich G, Verzini F, Haulon S, Waltham M, van Herwaarden JA, Holt PJ, van Keulen JW, Rantner B, Schlösser FJ, Setacci F, Ricco JB. Management of abdominal aortic aneurysms clinical practice guidelines of the European society for vascular surgery. *Eur J Vasc Endovasc Surg.* 2011 Jan;41(Suppl 1):S1-S58. doi: 10.1016/j.ejvs.2010.09.011
5. Patel R, Sweeting MJ, Powell JT, Greenhalgh RM. Endovascular versus open repair of abdominal aortic aneurysm in 15-years' follow-up of the UK endovascular aneurysm repair trial 1 (EVAR trial 1): a randomised controlled trial. *Lancet.* 2016 Nov 12;388(10058):2366-74. doi: 10.1016/S0140-6736(16)31135-7
6. Wanhainen A, Verzini F, Van Herzele I, Allaire E, Bown M, Cohnert T, Dick F, van Herwaarden J, Karkos C, Koelemay M, Kölbl T, Loftus I, Mani K, Melissano G, Powell J, Szeberin Z, Esvs Guidelines Committee, de Borst GJ, Chakfe N, Debus S, Hinchliffe R, Kakkos S, Koncar I, Kolh P, Lindholt JS, de Vega M, Vermassen F, Document Reviewers, Björck M, Cheng S, Dalman R, Davidovic L, Donas K, Earnshaw J, Eckstein HH, Golledge J, Haulon S, Mastracci T, Naylor R, Ricco JB, Verhagen H. Editor's Choice – European Society for Vascular Surgery (ESVS) 2019 Clinical Practice Guidelines on the Management of Abdominal Aorto-iliac Artery Aneurysms. *Eur J Vasc Endovasc Surg.* 2019 Jan;57(1):8-93. doi: 10.1016/j.ejvs.2018.09.020

7. Burke CR, Henke PK, Hernandez R, Rectenwald JE, Krishnamurthy V, Englesbe MJ, Kubus JJ, Escobar GA, Upchurch GR Jr, Eliason JL. A contemporary comparison of aortofemoral bypass and aortoiliac stenting in the treatment of aortoiliac occlusive disease. *Ann Vasc Surg.* 2010 Jan;24(1):4-13. doi: 10.1016/j.avsg.2009.09.005
8. Creager MA, Kaufman JA, Conte MS. Clinical practice. Acute limb ischemia. *N Engl J Med.* 2012 Jun 7;366(23):2198-206. doi: 10.1056/NEJMcp1006054
9. Huded CP, Goodney PP, Powell RJ, Nolan BW, Rzuclidlo EM, Simone ST, Walsh DB, Stone DH. The impact of adjunctive iliac stenting on femoral-femoral bypass in contemporary practice. *J Vasc Surg.* 2012 Mar;55(3):739-45; discussion 744-5. doi: 10.1016/j.jvs.2011.10.036
10. Becquemin JP, Pillet JC, Lescalie F, Sapoval M, Goueffic Y, Lermusiaux P, Steinmetz E, Marzelle J. A randomized controlled trial of endovascular aneurysm repair versus open surgery for abdominal aortic aneurysms in low- to moderate-risk patients. *J Vasc Surg.* 2011 May;53(5):1167-73.e1. doi: 10.1016/j.jvs.2010.10.124
11. Patel VI, Lancaster RT, Conrad MF, Lamuraglia GM, Kwolek CJ, Brewster DC, Cambria RP. Comparable mortality with open repair of complex and infrarenal aortic aneurysm. *J Vasc Surg.* 2011 Oct;54(4):952-59. doi: 10.1016/j.jvs.2011.03.231
12. Williams CR, Brooke BS. Effectiveness of open versus endovascular abdominal aortic aneurysm repair in population settings: A systematic review of statewide databases. *Surgery.* 2017 Oct;162(4):707-20. doi: 10.1016/j.surg.2017.01.014
13. Albuquerque FC Jr, Tonnessen BH, Noll RE Jr, Cires G, Kim JK, Sternbergh WC 3rd. Paradigm shifts in the treatment of abdominal aortic aneurysm: trends in 721 patients between 1996 and 2008. *J Vasc Surg.* 2010 Jun;51(6):1348-52; discussion 1352-53. doi: 10.1016/j.jvs.2010.01.078
14. Patel R, Powell JT, Sweeting MJ, Epstein DM, Barrett JK, Greenhalgh RM. The UK Endovascular Aneurysm Repair (EVAR) randomised controlled trials: long-term follow-up and cost-effectiveness analysis. *Health Technol Assess.* 2018 Jan;22(5):1-132. doi: 10.3310/hta22050
15. Kapma MR, Dijkstra LM, Reimerink JJ, de Groof AJ, Zeebregts CJ, Wisselink W, Balm R, Dijkgraaf MG, Vahl AC. Cost-effectiveness and cost-utility of endovascular versus open repair of ruptured abdominal aortic aneurysm in the Amsterdam Acute Aneurysm Trial. *Br J Surg.* 2014 Feb;101(3):208-15. doi: 10.1002/bjs.9356

### REFERENCES

1. Menard MT. Aortoiliac Disease: Direct Aortoiliac Reconstruction. In: Cronenwett JL, Johnston KW. Rutherford's Vascular Surgery. 8<sup>th</sup> ed. Philadelphia: Elsevier Saunders; 2014. p. 1701-21. <https://www.uk.elsevierhealth.com/rutherford-s-vascular-surgery-2-volume-set-9781455753048.html>
2. Jaquinandi V, Picquet J, Saumet JL, Benharash P, Leftheriotis G, Abraham P. Functional assessment at the buttock level of the effect of aortobifemoral bypass surgery. *Ann Surg.* 2008 May;247(5):869-76. doi: 10.1097/SLA.0b013e31816bcd75
3. Norgren L, Hiatt WR, Dormandy JA, Nehler MR, Harris KA, Fowkes FG, Rutherford RB. Inter-



- society consensus for the management of peripheral arterial disease (TASC II). *J Vasc Surg.* 2007 Jan;45(1 Suppl):S5-S67. doi: <https://doi.org/10.1016/j.jvs.2006.12.037>
4. Moll FL, Powell JT, Fraedrich G, Verzini F, Haulon S, Waltham M, van Herwaarden JA, Holt PJ, van Keulen JW, Rantner B, Schlösser FJ, Setacci F, Ricco JB. Management of abdominal aortic aneurysms clinical practice guidelines of the European society for vascular surgery. *Eur J Vasc Endovasc Surg.* 2011 Jan;41(Suppl 1):S1-S58. doi: [10.1016/j.ejvs.2010.09.011](https://doi.org/10.1016/j.ejvs.2010.09.011)
5. Patel R, Sweeting MJ, Powell JT, Greenhalgh RM. Endovascular versus open repair of abdominal aortic aneurysm in 15-years' follow-up of the UK endovascular aneurysm repair trial 1 (EVAR trial 1): a randomised controlled trial. *Lancet.* 2016 Nov 12;388(10058):2366-74. doi: [10.1016/S0140-6736\(16\)31135-7](https://doi.org/10.1016/S0140-6736(16)31135-7)
6. Wanhainen A, Verzini F, Van Herzele I, Allaire E, Bown M, Cohnert T, Dick F, van Herwaarden J, Karkos C, Koelemay M, Kölbl T, Loftus I, Mani K, Melissano G, Powell J, Szeberin Z, Esvs Guidelines Committee, de Borst GJ, Chakfe N, Debus S, Hinchliffe R, Kakkos S, Koncar I, Kolh P, Lindholt JS, de Vega M, Vermassen F, Document Reviewers, Björck M, Cheng S, Dalman R, Davidovic L, Donas K, Earnshaw J, Eckstein HH, Golledge J, Haulon S, Mastracci T, Naylor R, Ricco JB, Verhagen H. Editor's Choice – European Society for Vascular Surgery (ESVS) 2019 Clinical Practice Guidelines on the Management of Abdominal Aorto-iliac Artery Aneurysms. *Eur J Vasc Endovasc Surg.* 2019 Jan;57(1):8-93. doi: [10.1016/j.ejvs.2018.09.020](https://doi.org/10.1016/j.ejvs.2018.09.020)
7. Burke CR, Henke PK, Hernandez R, Rectenwald JE, Krishnamurthy V, Englesbe MJ, Kubus JJ, Escobar GA, Upchurch GR Jr, Eliason JL. A contemporary comparison of aortofemoral bypass and aortoiliac stenting in the treatment of aortoiliac occlusive disease. *Ann Vasc Surg.* 2010 Jan;24(1):4-13. doi: [10.1016/j.avsg.2009.09.005](https://doi.org/10.1016/j.avsg.2009.09.005)
8. Creager MA, Kaufman JA, Conte MS. Clinical practice. Acute limb ischemia. *N Engl J Med.* 2012 Jun 7;366(23):2198-206. doi: [10.1056/NEJMc1006054](https://doi.org/10.1056/NEJMc1006054)

#### Адрес для корреспонденции

04001, Словацкая Республика,  
г. Кошице, ул. Ондавская, д. 8,  
Восточно-Словацкий институт  
сердечно-сосудистых заболеваний,  
клиника сосудистой хирургии,  
тел.: + 421 055 789-15-10,  
e-mail: [i.kopolovets@gmail.com](mailto:i.kopolovets@gmail.com),  
Кополовец Иван

#### Сведения об авторах

Сиготски Владимир, PhD, заместитель заведующего клиникой сосудистой хирургии по педагогической работе, сосудистый хирург, Восточно-Словацкий институт сердечно-сосудистых заболеваний, университет П.И. Шафарика, медицинский факультет, г. Кошице, Словацкая Республика.  
<https://orcid.org/0000-0002-1446-8216>  
Кополовец Иван, к.м.н., сосудистый хирург, Восточно-Словацкий институт сердечно-сосудистых заболеваний, г. Кошице, Словакия, научный сотрудник ВГУЗ «Ужгородский национальный университет», г. Ужгород, Украина.

9. Huded CP, Goodney PP, Powell RJ, Nolan BW, Rzcuidlo EM, Simone ST, Walsh DB, Stone DH. The impact of adjunctive iliac stenting on femoral-femoral bypass in contemporary practice. *J Vasc Surg.* 2012 Mar;55(3):739-45; discussion 744-5. doi: [10.1016/j.jvs.2011.10.036](https://doi.org/10.1016/j.jvs.2011.10.036)
10. Becquemini JP, Pillet JC, Lescalie F, Sapoval M, Goueffic Y, Lermusiaux P, Steinmetz E, Marzelle J. A randomized controlled trial of endovascular aneurysm repair versus open surgery for abdominal aortic aneurysms in low- to moderate-risk patients. *J Vasc Surg.* 2011 May;53(5):1167-73.e1. doi: [10.1016/j.jvs.2010.10.124](https://doi.org/10.1016/j.jvs.2010.10.124)
11. Patel VI, Lancaster RT, Conrad MF, Lamuraglia GM, Kwolek CJ, Brewster DC, Cambria RP. Comparable mortality with open repair of complex and infrarenal aortic aneurysm. *J Vasc Surg.* 2011 Oct;54(4):952-59. doi: [10.1016/j.jvs.2011.03.231](https://doi.org/10.1016/j.jvs.2011.03.231)
12. Williams CR, Brooke BS. Effectiveness of open versus endovascular abdominal aortic aneurysm repair in population settings: A systematic review of statewide databases. *Surgery.* 2017 Oct;162(4):707-20. doi: [10.1016/j.surg.2017.01.014](https://doi.org/10.1016/j.surg.2017.01.014)
13. Albuquerque FC Jr, Tonnessen BH, Noll RE Jr, Cires G, Kim JK, Sternbergh WC 3rd. Paradigm shifts in the treatment of abdominal aortic aneurysm: trends in 721 patients between 1996 and 2008. *J Vasc Surg.* 2010 Jun;51(6):1348-52; discussion 1352-53. doi: [10.1016/j.jvs.2010.01.078](https://doi.org/10.1016/j.jvs.2010.01.078)
14. Patel R, Powell JT, Sweeting MJ, Epstein DM, Barrett JK, Greenhalgh RM. The UK EndoVascular Aneurysm Repair (EVAR) randomised controlled trials: long-term follow-up and cost-effectiveness analysis. *Health Technol Assess.* 2018 Jan;22(5):1-132. doi: [10.3310/hta22050](https://doi.org/10.3310/hta22050)
15. Kapma MR, Dijkstra LM, Reimerink JJ, de Groof AJ, Zeebregts CJ, Wisselink W, Balm R, Dijkgraaf MG, Vahl AC. Cost-effectiveness and cost-utility of endovascular versus open repair of ruptured abdominal aortic aneurysm in the Amsterdam Acute Aneurysm Trial. *Br J Surg.* 2014 Feb;101(3):208-15. doi: [10.1002/bjs.9356](https://doi.org/10.1002/bjs.9356)

#### Address for correspondence

04001, Slovakia,  
Kosice, Ondavska Str., 8,  
Eastern Slovak Institute  
of Cardiovascular Diseases.  
Tel. + 421 055 789-15-10,  
e-mail: [i.kopolovets@gmail.com](mailto:i.kopolovets@gmail.com),  
Ivan Kopolovets

#### Information about the authors

Sihotský Vladimir, PhD, Deputy Head of the Clinic of Vascular Surgery for Pedagogical Work, Vascular Surgeon, Eastern Slovak Institute of Cardiovascular Diseases, Pavol Jozef Safarik University, Medical Faculty, Kosice, Slovak Republic.  
<https://orcid.org/0000-0002-1446-8216>  
Kopolovets Ivan, PhD, Vascular Surgeon, Eastern Slovak Institute of Cardiovascular Diseases, Košice, Slovak Republic, Researcher of Uzhhorod National University, Uzhhorod, Ukraine.  
<http://orcid.org/0000-0002-2721-6114>  
Kubiková Maria, PhD, Vascular Surgeon, Eastern

<http://orcid.org/0000-0002-2721-6114>

Кубикова Мария, PhD, сосудистый хирург, Восточно-Словацкий институт сердечно-сосудистых заболеваний, университет П.И. Шафарика, медицинский факультет, г. Кошице, Словацкая Республика. <https://orcid.org/0000-0001-5628-8814>

Штефанич Петер, PhD, сосудистый хирург, Восточно-Словацкий институт сердечно-сосудистых заболеваний, университет П.И. Шафарика, медицинский факультет, г. Кошице, Словацкая Республика. <http://orcid.org/0000-0002-0396-3676>

Катюх Владимир, PhD, заведующий клиникой нейрохирургии, университет П.И. Шафарика, медицинский факультет, г. Кошице, Словацкая Республика. <http://orcid.org/0000-0001-8044-4012>

Slovak Institute of Cardiovascular Diseases, Pavol Jozef Safarik University, Medical Faculty, Kosice, Slovak Republic.

<https://orcid.org/0000-0001-5628-8814>

Stefanic Peter, PhD, Vascular Surgeon, Eastern Slovak Institute of Cardiovascular Diseases, Pavol Jozef Safarik University, Medical Faculty, Kosice, Slovak Republic.

<http://orcid.org/0000-0002-0396-3676>

Katuch Vladimir, PhD, Head of the Neurosurgery Clinic, Pavol Jozef Safarik University, Medical Faculty, Kosice, Slovak Republic.

<http://orcid.org/0000-0001-8044-4012>

#### Информация о статье

*Получена 8 октября 2018 г.*

*Принята в печать 30 мая 2019*

*Доступна на сайте 1 июля 2019 г.*

#### Article history

*Arrived: 08 October 2018*

*Accepted for publication 30 May 2019*

*Available online: 1 July 2019*